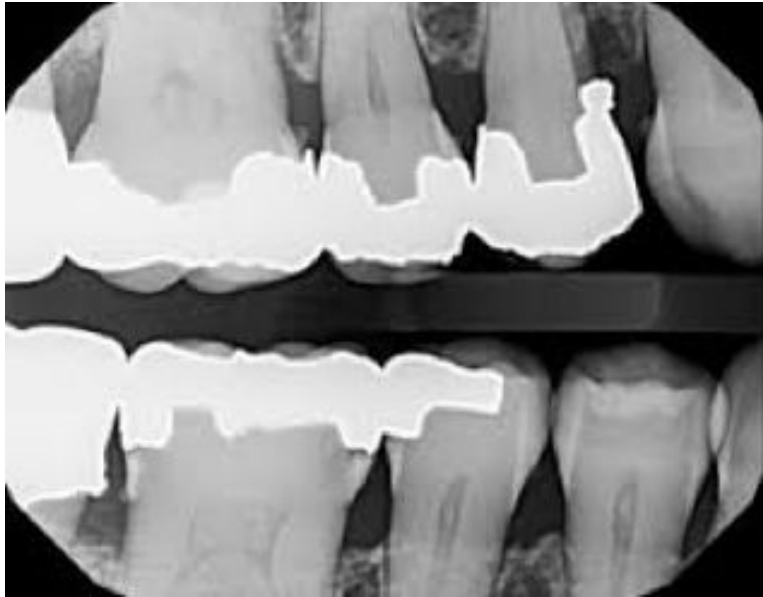


The amalgam restoration in tooth #5 was placed 20 years ago and the margins appear sealed. The patient reports no issues with the tooth or surrounding area. The mesial contact is open and there is significant overhang. Pocket depths are WNL and there is no sign of clinical inflammation.



Steven Resnick, DDS  
Asst. Chair, Sr. Director of Clinical Education  
Dept. of Cariology and Comprehensive Care

What is your next step?

1. Attempt to remove the overhang with a diamond stone
2. Provide no treatment but inform the patient of the existing condition
3. Use the existing amalgam as a core, prepare and restore the tooth with a full coverage restoration.
4. Remove the amalgam and replace with composite to eliminate the overhang and restore contact.
5. Remove the mesial portion of the amalgam and replace with composite
6. Remove the overhang with an abrasive strip
7. Restore #11 with composite to close the contact

Correct Answer(s): 2