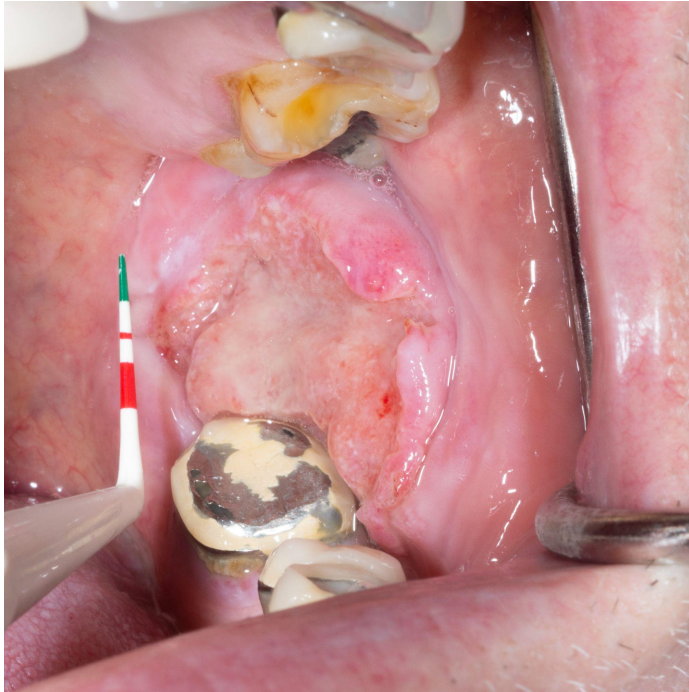


Microjudgement: Knowing the correct course of action for this patient.

What is the most appropriate immediate management for this patient?

1. Ask patient to return in 4 weeks for another check.
2. Obtain a tissue specimen/biopsy (correct answer)
3. Smooth/polish the adjacent teeth
4. Swab the lesion for yeast
5. Treat with an antibiotic
6. Treat with a systemic antifungal



Eli Whitney DDS, FRCD(C)
Certified Specialist in Oral Medicine and Pathology
Associate Professor of Teaching
DMD Curriculum Director
Dentistry | Oral Biological and Medical Science



THE UNIVERSITY OF BRITISH COLUMBIA